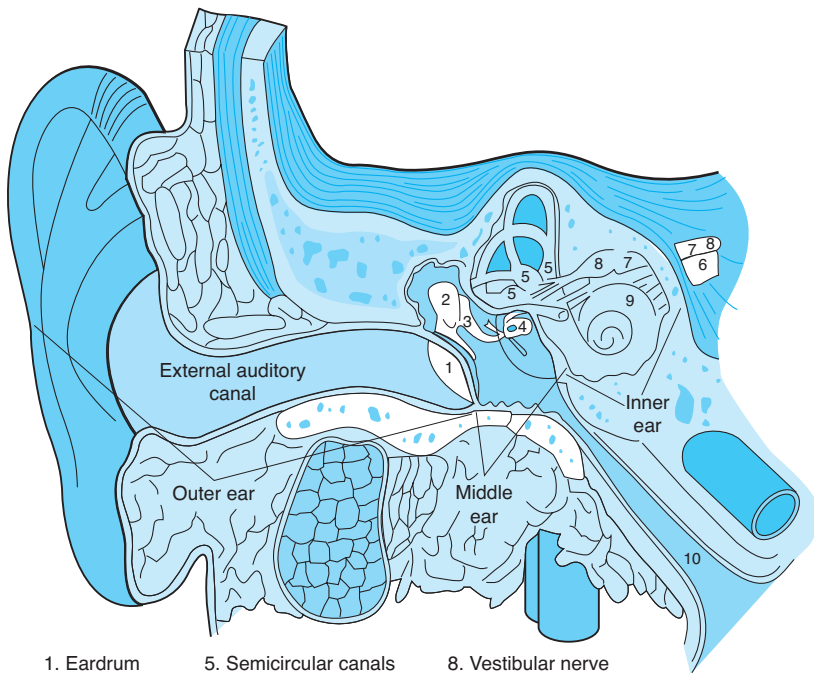



- | | | |
|------------|------------------------|---------------------|
| 1. Eardrum | 5. Semicircular canals | 8. Vestibular nerve |
| 2. Malleus | 6. Auditory nerve | 9. Cochlea |
| 3. Incus | 7. Facial nerve | 10. Eustachian tube |
| 4. Stapes | | |

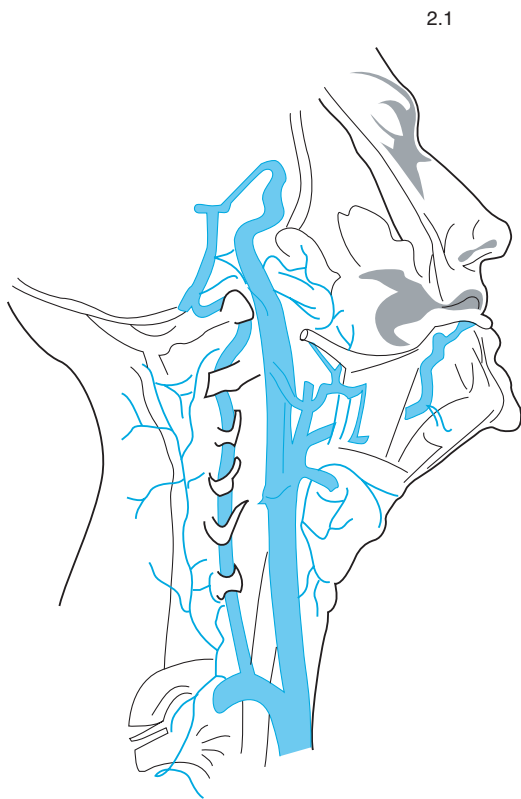
(a) Normal bone



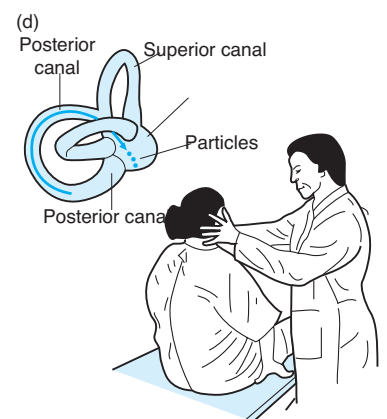
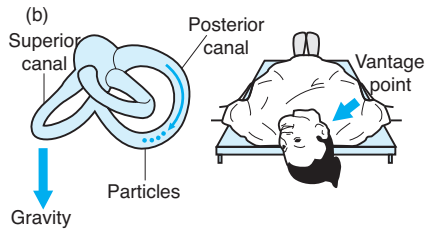
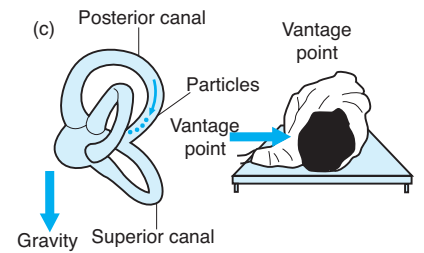
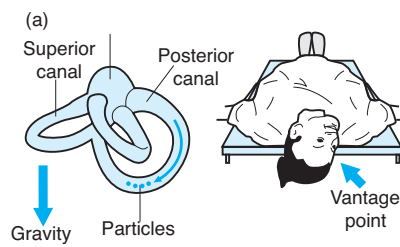
(b) Osteoporotic bone

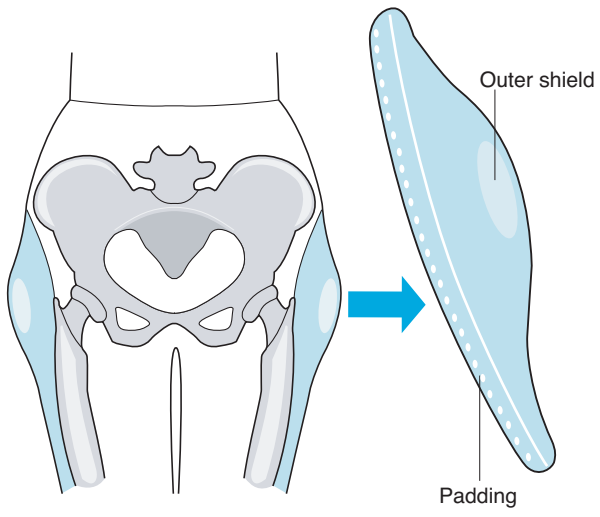


14.1

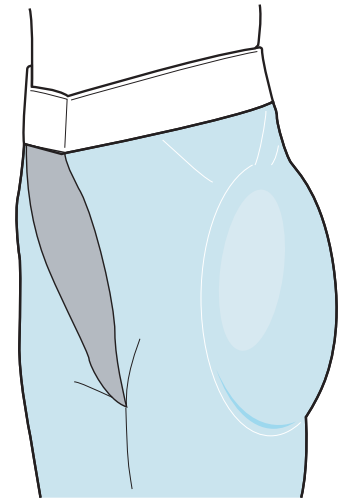


9.2



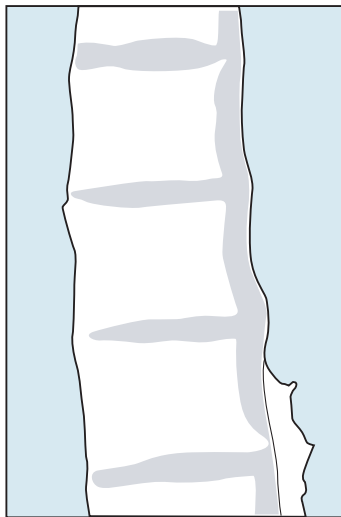


14.4

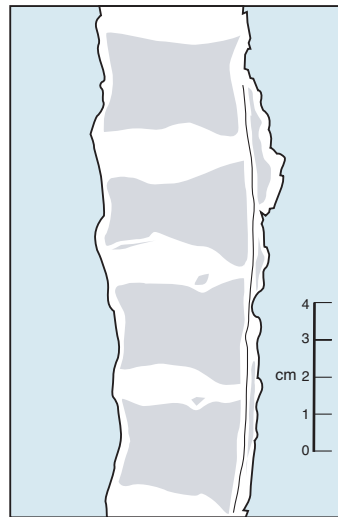


14.5

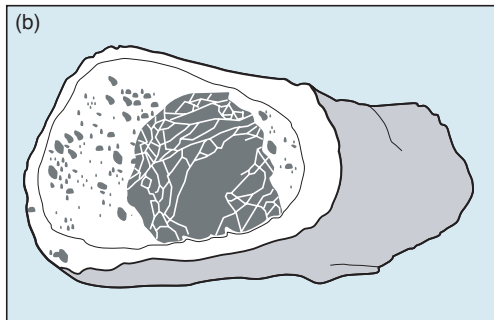
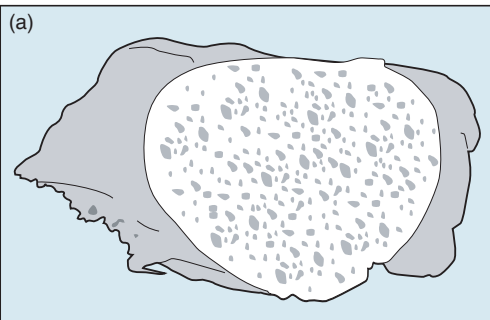
(a) Normal vertebrae



(b) Osteoporotic vertebrae



14.3



14.2